

Therapy Update

ENT

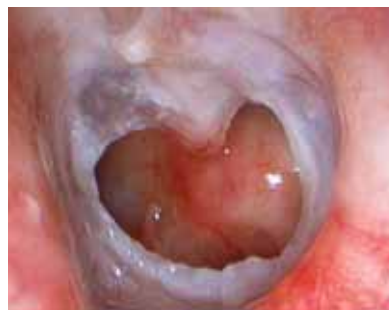
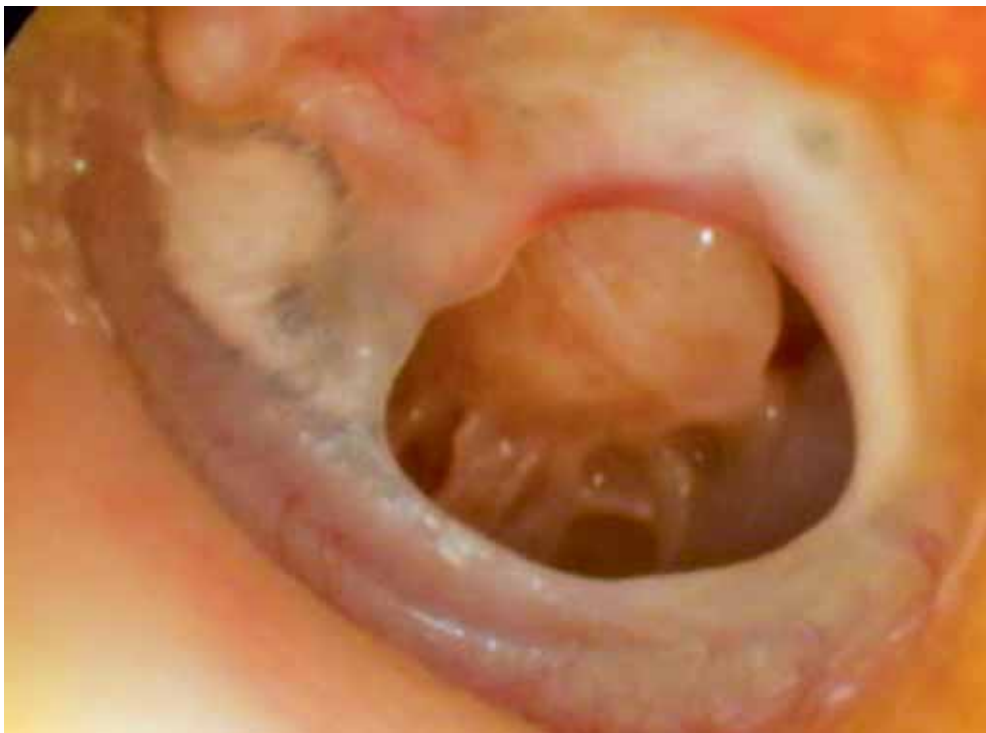
Figure 1 (left): Otoscopic view of a left ear with a central perforation. The ear is inflamed and moist.

Figure 2 (left): Otoscopic view of a left ear with a central perforation. The ear is dry with normal middle ear mucosa. Note the tympanosclerosis in the anterior and posterior drum remnant.

TYMPANIC MEMBRANE PERFORATIONS

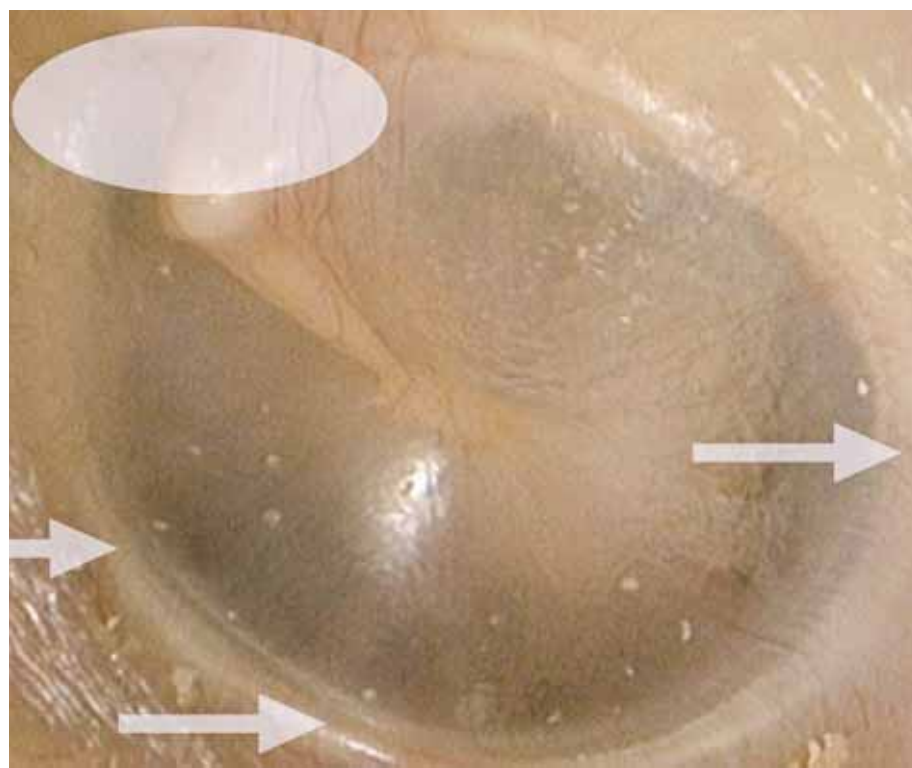


Figure 3: Otoscopic view of a normal left ear. The shaded oval represents the attic of the ear and the white arrows are pointing to the annulus or margins of the tympanic membrane.



Can you distinguish between safe and unsafe perforations? DR NIRMAL PATEL tells you how.

Case study

A 35-YEAR-OLD female presents with intermittent discharge from her right ear whenever she has an upper respiratory tract infection or gets her ears wet.

She has started to notice declining hearing in the same ear over the past two years. The patient has a medical history of recurrent ear infections as a child. On examination, she has a large perforation of the eardrum (see figure 1) with inflamed middle

ear mucosa as well as conductive hearing loss on tuning fork testing.

Natural history

Tympanic membrane perforations are holes in the eardrum that most commonly occur as a consequence of either ear infections or trauma to the ear.

Acute middle ear infection (acute otitis media) is a common condition occurring at least once in 80% of children. Most acute otitis media resolves with spontaneous discharge

Acute middle ear infection ... is a common condition occurring at least once in 80% of children.

of infected secretions through the eustachian tube into the nasopharynx. Occasionally, when there is significant eustachian tube obstruction — commonly from immaturity of the tube or from adenoid hypertrophy — then there may be resolution of the infection by perforation of the tympanic membrane.

Most acute tympanic membrane perforations from infection spontaneously resolve with treatment of the infection. Occasionally, when the infections are frequent, there is

extensive scarring (tympanosclerosis) of the eardrum and middle ear (see figure 2). This compromises the blood supply to the healing eardrum and, occasionally, stops the hole from healing. These patients often have discharging ears when there is water exposure or with upper respiratory tract infections.

With frequent ear infections in children that fail to resolve with medical therapy, grommets (middle ear ventilation tubes) are sometimes

cont'd next page

74% of your patients search online for health information*

Send them somewhere you can trust

ItsMyHealth.com.au

Brought to you by the publisher of **Doctor**

*Source: The Nielsen 2010 Australian Online Consumer Report

THERAPY UPDATE

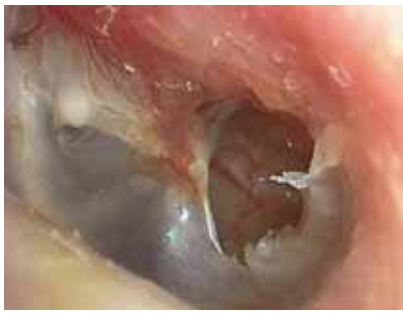

Figure 4 (above): Otoscopic view of a left ear with a marginal (unsafe) perforation. Note the perforation extending to the annulus of the tympanic membrane and also inferiorly, the white squamous epithelium migrating into the middle ear.

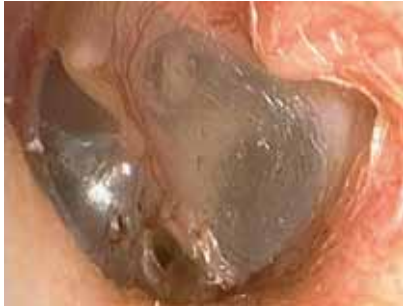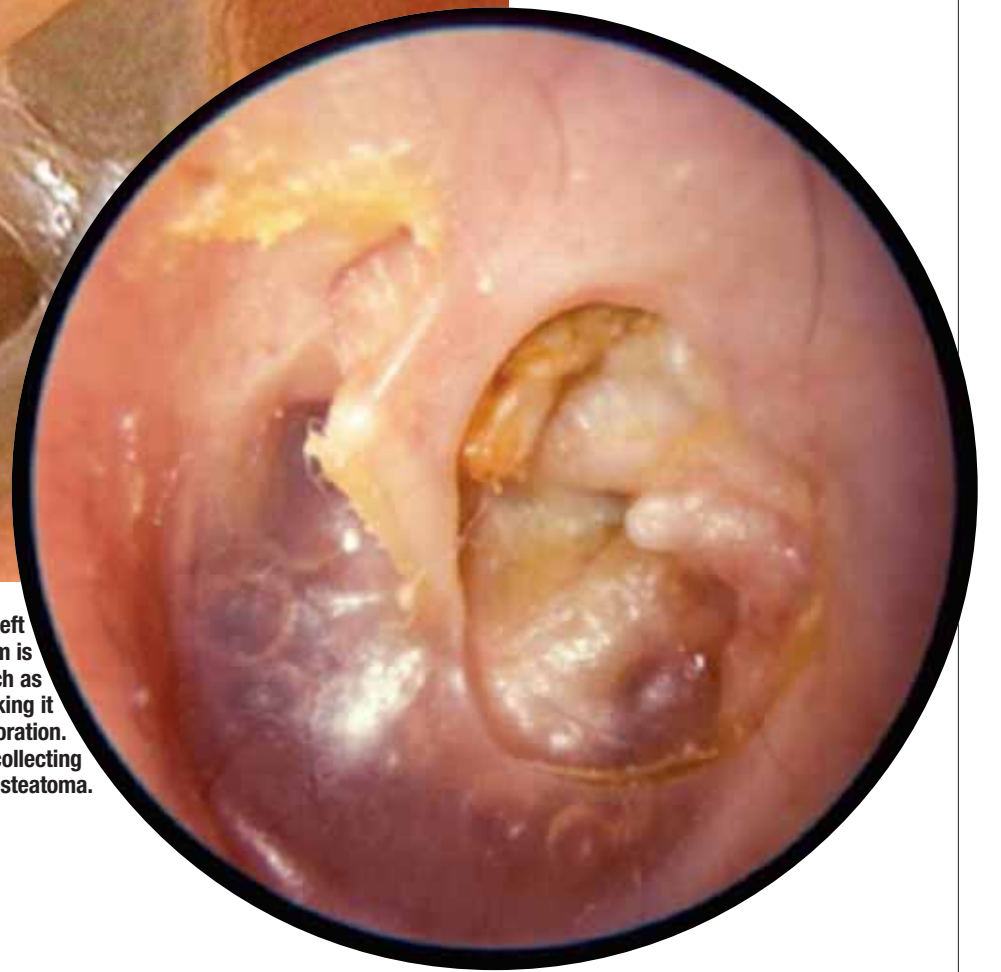


Figure 5 (above): Otoscopic view of a left ear with a marginal (unsafe) perforation. If untreated, a cholesteatoma may develop in this ear.

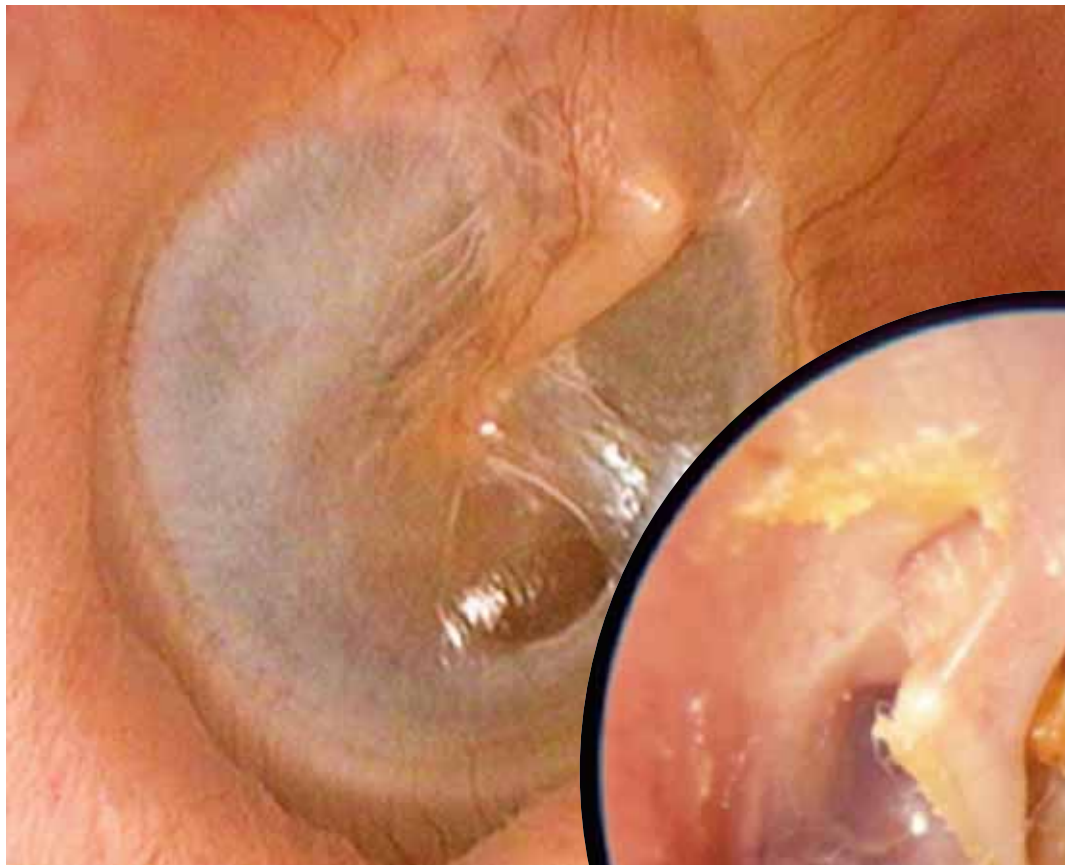

Figure 7 (right): Otoscopic view of a left retraction pocket. The retracted eardrum is draped over middle ear structures such as the stapes bone and facial nerve, making it easy to misdiagnose this as a perforation. Note the squamous epithelium collecting superiorly, a sign of cholesteatoma.

Figure 6 (left): Otoscopic view of a right ear with a thin (dimeric) area following a healed perforation. This can be misdiagnosed as a perforation.



from previous page

recommended by the ENT surgeon. The grommet tube reduces the frequency and severity of ear infections by ventilating the middle ear and bypassing a blocked eustachian tube.

Rarely, when the grommet tube falls out, or when it is removed, the hole in the eardrum does not heal spontaneously. This is typically due to persistent eustachian tube dysfunction and tympanosclerosis, causing poor blood supply to the healing eardrum.

Traumatically induced holes occur from a rapid compression of the air column in the external ear canal, most commonly from a blow to the side of the head. In the Australian population this occurs most frequently with water skiing or surfing accidents, or in children with accidental blows to the side of the head.

Diagnosis basics

Examination of the ear is divided into anatomical inspection (otoscopic and microscopic) and physiological assessment (clinical hearing and balance testing).

A tympanic membrane perforation is diagnosed when a deficiency in the eardrum is noted.

The location of the perforation in the eardrum is clinically relevant. The pars flaccida region of the tympanic membrane is that region above the short process of the malleus (see figure 3). Typically, this area is called the attic region and is clean and smooth, with a few blood vessels noted. If this region is not smooth and free of wax/debris and, in particular, if a perforation can be seen in the attic, then there is a possibility it is a cholesteatoma — an epithelial inclusion cyst of the tem-

poral bone, which often requires surgical intervention (see 'Update on cholesteatoma', Therapy Update, 20 May 2011).

The annulus of the eardrum delineates the margin.

The unsafe ear

When either a marginal or an attic perforation is seen, this is an unsafe situation. An attic perforation is a hole above the short process of the malleus. A marginal perforation is one where the hole reaches the annulus of the eardrum (see figures 4 and 5). Both of these situations can disturb the normal flow of epithelium from the tympanic membrane out of the external auditory canal and may be a sign of cholesteatoma.

Common misdiagnoses

Two common misdiagnoses are made: calling a thin tympanic membrane a hole in the eardrum; and, calling a retracted tympanic membrane a hole in the eardrum.

Thin eardrums (dimeric segments) occur with spontaneous closure of the perforation where the healed segment lacks the fibrous (structural) layer. This creates a part of the eardrum where it is often easier to see middle ear structures and therefore it looks like a hole in the eardrum (see figure 6). Pneumatic otoscopy, moving the eardrum with a sealed speculum, easily differentiates a thin eardrum from the eardrum with a hole — the latter will not move with insufflation.

Retracted eardrums (atelectasis) occur due to persistent eustachian tube dysfunction. The healing eardrum collapses onto the structures of the middle ear. The thin retracted eardrum draped over the medial wall of the ear outlines

Traumatically induced holes occur from a rapid compression of the air column in the external ear canal, most commonly from a blow to the side of the head.

middle ear structures, again making it easy to mistake this for a hole (see figure 7). Sometimes the diagnosis of retraction can only be confirmed under high-powered microscopy.

Management

Most acute perforations from infection will spontaneously heal with culture-directed antibiotic treatment of the ear infection. Most acute traumatic perforations will also heal spontaneously. If the middle ear is soiled then antibiotics (such as amoxicillin) are used for a week. The patient should maintain strict water precautions and be regularly checked until the hole heals, usually within a few weeks. Occasionally, the acute perforations will not heal and then

they are defined as chronic.

If a patient is asymptomatic, then most dry safe central perforations are left alone. If the patient is symptomatic, dry safe chronic perforations are managed surgically. The patient will usually complain of either discharge from the ear or hearing loss. In this case, some form of tympanoplasty (repair of the eardrum and/or ear bones) is required.

Unsafe perforations are generally managed surgically to treat the underlying cholesteatoma or prevent cholesteatoma formation. Broadly, two techniques are offered — conservative (intact canal wall mastoidectomy or atticotomy) or radical (modified radical or radical mastoidectomy). The main purpose is to remove the disease and create a safe, dry ear. A secondary benefit may be restoration of hearing.

A surgical video is available for viewing at youtube.com/watch?v=DJSEpg7BiyQ

When to refer

- Attic or marginal perforation (especially if patient is symptomatic).
- Central perforation that is symptomatic (discharge or hearing loss).
- Retracted eardrum with squamous debris collecting.
- Retracted eardrum with symptomatic hearing loss. ●

Dr Patel is associate professor of surgery at Macquarie University, clinical senior lecturer at the University of Sydney, and director of the Kolling Deafness Research Centre.

Acknowledgements

The author thanks Dr John Kelly for some otoscopic pictures.

VERY IMPORTANT FACTS

Red flags

- Marginal perforations
- Attic perforations
- Chronically discharging or bleeding ear
- Perforation with significant clinical hearing loss

Key diagnoses

- Safe perforations — dry and central, away from the attic or the annulus margins. These will generally not progress to serious pathology.
- Unsafe perforations — attic, marginal and chronically discharging perforations. These may progress to serious pathology.
- Thin tympanic membrane (dimeric segment)
- Retracted tympanic membrane (atelectasis)